VOLUME 30 · NUMBER 29 · OCTOBER 10 2012

JOURNAL OF CLINICAL ONCOLOGY

DIAGNOSIS IN ONCOLOGY

Cancer of Unknown Primary: From Immunohistochemistry to Gene Expression Profiling

Case Report

In April 2011, a 70-year-old Chinese man was referred to our cancer center for evaluation of a nodule on the right lower eyelid (Fig 1) that was growing in size since it was first noticed 9 months previously. He was in a normal state of health and had no significant past medical history except a smoking history of 50 pack-years. The patient presented to his primary care physician with a painless eyelid lesion and was referred to an oculoplastic surgeon for additional evaluation. The patient had no symptoms of weight loss, eye discomfort, pain, or discharge, visual loss, or respiratory or GI symptoms. He denied a family history of cancers. Socially, the patient was a retired farmer and had no history of significant chemical exposures.

The physical examination at the time of his visit was unremarkable, aside from a nonulcerative, nondraining nodular lower eyelid lesion. An orbital computed tomography scan of the patient showed a 21 × 12 × 7-mm enhancing lesion arising from the right inferior eyelid and abutting the inferior aspect of the globe. A biopsy was performed that revealed an infiltrating adenocarcinoma with positive cytokeratin (CK) 7, CK19, polyclonal carcinoembryonic antigen, carboxylesterase (CEA), and periodic acid-Schiff stains (Fig 2A, hematoxylin and eosin stain; Fig 2B, CK7 stain). Other immunohistochemical (IHC) stains performed, including thyroid transcriptase factor-1 (TTF-1), napsin A, CK20, renal cell carcinoma (RCC), CD10, paired box gene 8, caudal type homeo box 2, carbohydrate 19-9, glypican 3, D2-40, prostate-specific acid phosphatase (PSAP), mucicarmine, estrogen receptor, progesterone receptor, and gross cystic disease fluid protein-15 (GCDFP-15), were negative. The clinical findings coupled with immunohistochemical profile strongly suggested a metastatic adenocarcinoma, but the primary site remained unknown.

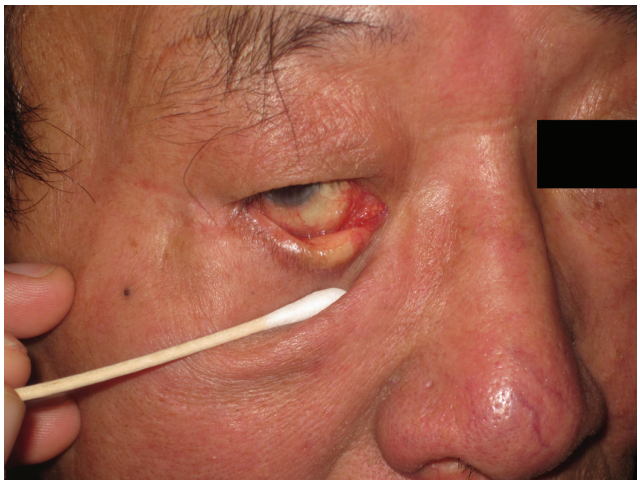

Fig 1.

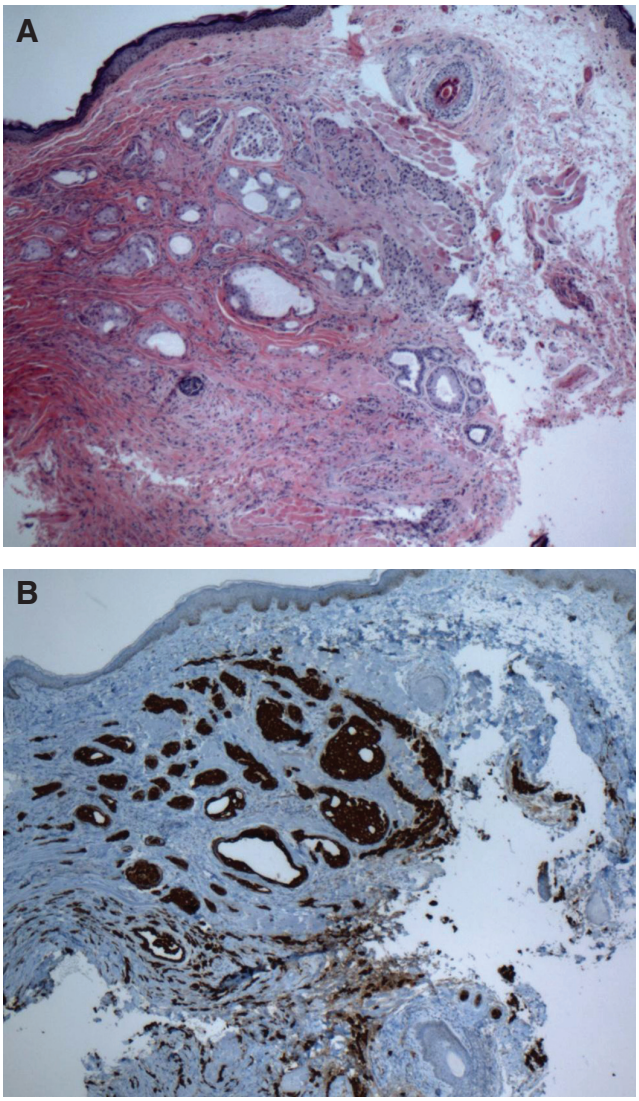

Fig 2.

Computed tomography imaging studies of the chest, abdomen, and pelvis failed to reveal other metastatic sites or a primary tumor. A physical examination of the patient was unremarkable. The CBC, serum chemistry, liver function, and renal function were all normal. Serologic tumor markers CEA, prostate-specific antigen, lactate dehydrogenase, CA 19-9, α-fetoprotein, β-human chorionic gonadotropin, and CA125 were all within normal limits.

Additional studies included magnetic resonance imaging of the abdomen, a positron emission tomography scan, and colonoscopy,

TISSUE OF ORIGIN TEST RESULTS

Data Quality: Acceptable

TISSUE	SIMILARITY SCORE
Breast	81.3
Colorectal	6.2
Non-Small Cell Lung	4.9
Prostate	1.4
Ovarian	1.1
Testicular Germ Cell	0.9
Gastric	0.7
Thyroid	0.7
Sarcoma	0.7
Pancreas	0.7
Kidney	0.6
Non-Hodgkin's Lymphoma	0.4
Hepatocellular	0.2
Melanoma	0.2
Bladder	0.1



Fig 3.

which did not reveal a primary tumor site. The patient underwent another biopsy of his eyelid, which was sent for mRNA testing for the cell of origin (Pathwork Diagnostics, Sunnyvale, CA; Fig 3).

The test results strongly supported a breast cancer as the cell of origin with a score of 81.3. The Pathwork Tissue of Origin test (Pathwork Diagnostics) uses measurements of the levels of 2,000 different mRNAs to determine the most likely tissue of origin for an unknown sample from among a panel of 15 different tumors. The similarity-score test result is considered diagnostic if the highest similarity score is greater than 20, and this report confirms the cell of origin with 99% certainty.

The patient underwent another careful examination after the tissue-of-origin test with attention paid to the breast region, and it was again within normal limits. A mammogram was negative. The paucity of breast tissue on physical examination precluded magnetic resonance imaging. *BRCA* mutation testing was negative. Our recommendation was to treat the patient with local radiation therapy with concurrent systemic chemotherapy with carboplatin. The patient declined concurrent chemotherapy but had completed radiation therapy with a near-complete clinical response. His follow-up visit 2 and 5 months post-treatment did not show evidence of disease recurrence or progression.

Discussion

Cancer of unknown primary (CUP) is defined as metastatic cancer in the absence of a clinically detectable anatomically defined primary tumor site after an adequate diagnostic evaluation.[1] There were more than 30,000 new cases of cancer of unknown origin in the United States in 2010 according to Surveillance, Epidemiology and End Results data.[2] Almost one third[3] of all cancers present with metastatic disease, and the primary sites remain uncertain in many patients. A recent analysis suggested the number of cancers may actually be much higher than previously thought, with more than 50,000 CUP cases per year.[4] CUP patients do poorly as a group with a median survival as low as 3 to 4 months.[1]

The genomic profiling for the primary site of origin in this patient was provocative because male breast cancer is so rare and accounts for less than 1% of all cancers in men and less than 1% of breast cancers.[5] The metastatic pattern at diagnosis for this patient was atypical for breast cancer. Although patients with known breast cancer have been reported to metastasize to the eyelid,[6,7,8] it is still a rare phenomenon. Several reports have illustrated that orbital findings typically present after, but not before, diagnosis of breast cancer and commonly present late during the course with diffuse metastatic involvement.[9,10] Nevertheless, most eye metastases reported in the literature include choroid, anterior chamber, uvea, and other parts of the orbit but rarely the eyelid.[6,11] Interestingly, to our knowledge, no literature has been published on the IHC characteristics of these orbit metastases originating from breasts. Although the CK7-positive and CK20-negative IHC staining were consistent with breast cancer in this case, more-corroborating IHC stains for breast origin were lacking, especially with a negative GCDFP-15 stain, which has been found to have a high association with primary breast carcinoma.[13]

Immunohistochemistry analysis is a vital component in the investigation of CUP cancers.[14] However, the analysis has limitations because markers for CUP are not uniformly site specific or sensitive. There are published systematic IHC algorithms[15] for the evaluation of CUP cases, but there remains a poor consensus as to the extent of IHC stains used when the initial evaluation remains ambiguous as to the primary cell of origin. In this case, the IHC analysis did not appear to provide clarity for the primary site. Eighteen IHC stains were used, but the paucity of positive stains precluded primary site identification. A lung primary is unlikely with negative TTF-1 and napsin A, a pancreatic primary with negative IHC and serum CA 19-9, a renal primary with negative RCC and CD10, and prostate with negative PSAP. There still remains a wide range of differential diagnoses on the basis of positive CEA, negative TTF-1, positive CK7, and negative CK20. This lack of pathologic clarity typifies CUP cases in which IHC staining lacks site-specific expression patterns.

During the past 40 years, one thing that has not changed with CUP cases is that metastatic patterns at diagnosis rarely mimic the familiar metastatic patterns at first relapse in known primary cancers. What does appear to be changing is the distribution of primary sites with genomic testing. A relative proportion of autopsy-found primaries are significantly different than the relative proportion of molecularly profiled primaries. Breast cancer, which contributed to approximately 1%

of autopsy-found primaries, now constitutes a significant portion of 12% to 13% of CUP cases.[16]

Genomically derived test results often provide an unexpected cell of origin, but validity studies that used genomic testing to identify the cell of origin on blinded specimens of known primary cancers have been peer reviewed, rigorous, and accurate.[17,18,19,20] There have been other studies that reported clinicopathologic correlative data that suggested the usefulness of molecular assays in predicting correct primary sites[21,22] and guiding the management of CUP cases. Currently, because molecular analysis is becoming an integral tool to provide more-accurate diagnosis,[23] several commercial molecular gene expression–based assays (Tissue of Origin test [Pathwork Diagnostics], CancerType ID [BioTheranostics, San Diego, CA], and MiRview Mets test [Rosetta Genomics, Philadelphia, PA; Rehovot, Israel]) for CUP are available with prediction accuracies in known primary cancers of 80% to 90%.[24] Molecular assays have been shown to compare favorably with IHC-marker stains and have been found to often provide a single correct prediction of the primary tumor site (75% *v* 25%, respectively).[25]

The clinical management of this patient as a result of the resultant diagnosis would have been significantly different had we not used the molecular profiling. Genetic testing was offered to this patient because identifying breast cancer as primary site of origin created an impact on him, his children, and other family members. Approximately 10% of men with breast cancer have a genetic predisposition with *BRCA* mutations.[26,27,28] The selection of treatment modalities and chemotherapy would be drastically different for metastatic adenocarcinoma in the head and neck compared with metastatic breast carcinoma had the patient not declined therapy. Ultimately, identifying the cell of origin should greatly facilitate the management of many of these cancers with unknown primaries.

In conclusion, this case is representative of the atypical nature of CUP with respect to nonspecific IHC staining patterns and clinical presentation. Historically, necropsy had been the most-accurate method of determining the cell of origin, but it fails greater than 50% of the time to provide a cell of origin, likely as a result of the microscopic tumor in nature, and it certainly cannot be a treatment planning tool. Genomic testing is fast becoming an effective way of identifying the cell of origin as it did in this case. As we gain experience with genomic testing, it will become an integral tool used in directing future therapeutic decisions in patients with cancers of unknown origins.

Wendy M. Chiang, Mitesh Kapadia, Nora V. Laver, and John Scott Nystrom
Tufts Medical Center, Boston, MA

AUTHORS' DISCLOSURES OF POTENTIAL CONFLICTS OF INTEREST

The author(s) indicated no potential conflicts of interest.

REFERENCES

1. Greco FA, Hainsworth JD: Cancer of unknown primary site, in Devita VT Jr, Hellman S, Rosenberg (eds): Cancer: Principles and Practice of Oncology (ed 8). Philadelphia, PA, Lippincott, 2008, pp 2363-2387

2. Jemal A, Siegel R, Ward E, et al: Cancer statistics, 2009. CA Cancer J Clin 59:225-249, 2009

3. Varadhachary GR, Abbruzzese JL, Lenzi R: Diagnostic strategies for unknown primary cancer. Cancer 100:1776-1785, 2004

4. Tong KB, Murtagh KN, Hubert HB, et al: Incidence, costs of care and survival of Medicare beneficiaries diagnosed with carcinoma of unknown primary (CUP). Presented at the Association of Molecular Pathology Annual Meeting, Orlando, FL, November 17, 2006

5. Korde LA, Zujewski JA, Kamin L, et al: Multidisciplinary meeting on male breast cancer: Summary and research recommendations. J Clin Oncol 28:2114-2122, 2010

6. Zhang GJ, Adachi I, Yin DF, et al: Eyelid metastasis from breast cancer showing marked response to chemotherapy. Jpn J Clin Oncol 25:10-15, 1995

7. Albert DM, Rubenstein RA, Scheie HG: Tumor metastasis to the eye. I. Incidence in 213 adult patients with generalized malignancy. Am J Ophthalmol 63:723-726, 1967

8. Demirci H, Shields CL, Chao AN, et al: Uveal metastasis from breast cancer in 264 patients. Am J Ophthalmol 136:264-271, 2003

9. Francone E, Murelli F, Paroldi A, et al: Orbital swelling as a first symptom in breast carcinoma diagnosis: A case report. J Med Case Rep 4:211, 2010

10. Valenzuela AA, Archibald CW, Fleming B, et al: Orbital metastasis: Clinical features, management and outcome. Orbit 28:153-159, 2009

11. Ratanatharathorn V, Powers WE, Grimm J, et al: Eye metastasis from carcinoma of the breast: Diagnosis, radiation treatment and results. Cancer Treat Rev 18:261-276, 1991

12. Reference deleted

13. Park SY, Kim BH, Kim JH, et al: Panels of immunohistochemical markers help determine primary sites of metastatic adenocarcinoma. Arch Pathol Lab Med 131:1561-1567, 2007

14. National Comprehensive Cancer Network. NCCN clinical practice guidelines in oncology – Occult primary (cancer of unknown primary), Version 1.2012. http://www.nccn.org/professionals/physician_gls/pdf/occult.pdf

15. Bhargava R, Dabbs D: Diagnostic immunohistochemistry – Theranostic and genomic applications, in Immunohistology of Metastatic Carcinomas of Unknown Primary (ed 3). Philadelphia, PA, Saunders, 2010

16. Pentheroudakis G, Golfinopoulos V, Pavlidis N: Switching benchmarks in cancer of unknown primary: From autopsy to microarray. Eur J Cancer 43:2026-2036, 2007

17. Ma XJ, Patel R, Wang X, et al: Molecular classification of human cancers using a 92-gene real-time quantitative polymerase chain reaction assay. Arch Pathol Lab Med 130:465-473, 2006

18. Talantov D, Baden J, Jatkoe T, et al: A quantitative reverse transcriptase-polymerase chain reaction assay to identify metastatic carcinoma tissue of origin. J Mol Diagn 8:320-329, 2006

19. Rosenfeld N, Aharonov R, Meiri E, et al: MicroRNAs accurately identify cancer tissue origin. Nat Biotechnol 26:462-469, 2008

20. Monzon FA, Lyons-Weiler M, Buturovic LJ, et al: Multicenter validation of a 1,550-gene expression profile for identification of tumor tissue of origin. J Clin Oncol 27:2503-2508, 2009

21. Varadhachary GR, Talantov D, Raber MN, et al: Molecular profiling of carcinoma of unknown primary and correlation with clinical evaluation. J Clin Oncol 26:4442-4448, 2008

22. Horlings HM, van Laar RK, Kerst JM, et al: Gene expression profiling to identify the histogenetic origin of metastatic adenocarcinomas of unknown primary. J Clin Oncol 26:4435-4441, 2008

23. Varadhachary GR, Spector Y, Abbruzzese JL, et al: Prospective gene signature study using microRNA to identify the tissue of origin in patients with carcinoma of unknown primary. Clin Cancer Res 17:4063-4070, 2011

24. Pollack A: Genetic tests may reveal source of mystery tumors. New York Times on the Web, March 10, 2009. http://www.nytimes.com/2009/03/10/health/10tumo.html?pagewanted=all

25. Greco FA, Spigel DR, Yardley DA, et al: Molecular Profiling in unknown primary cancer: Accuracy of tissue of origin prediction. Oncologist 15:500-506, 2010

26. Couch FJ, Farid LM, DeShano ML, et al: BRCA germline mutations in male breast cancer cases and breast cancer families. Nat Genet 13:123-125, 1996

27. Haraldsson K, Loman N, Zhang QX, et al: BRCA2 germ-line mutations are frequent in male breast cancer patients without a family history of the disease. Cancer Res 58:1367-1371, 1998

28. Thorlacius S, Tryggvadottir L, Olafsdottir GH, et al: Linkage to BRCA2 region in hereditary male breast cancer. Lancet 346:544-545, 1995

DOI: 10.1200/JCO.2011.41.1827; published online ahead of print at www.jco.org on September 10, 2012